

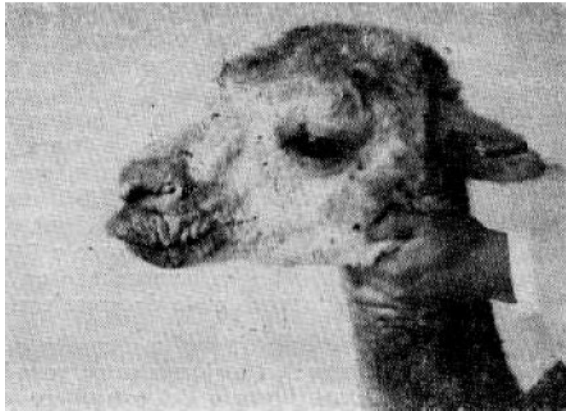

The Myth, the Mites and the Munge

A suggested remedy from Mike Safley for those troublesome alpaca skin problems.

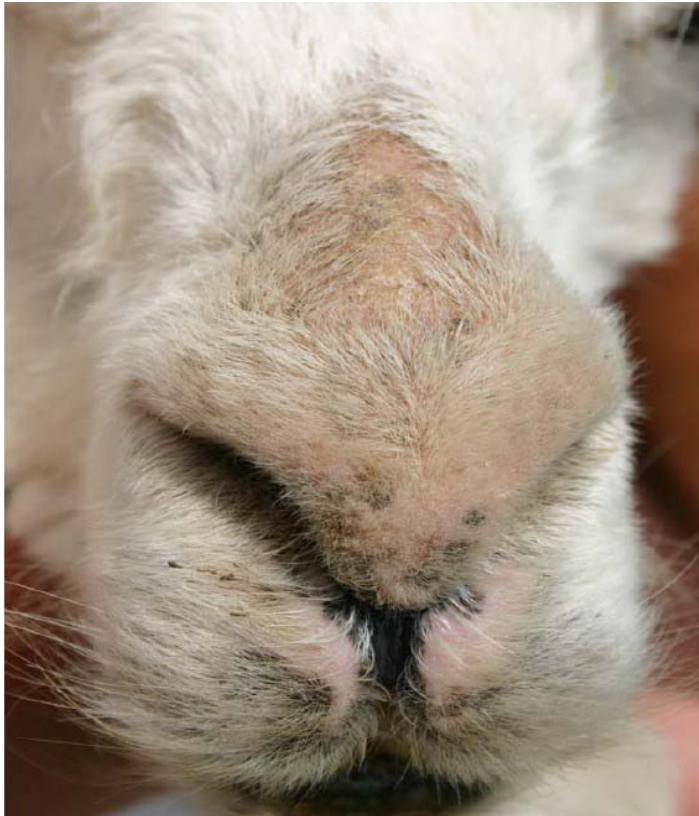
I remember slowly bending over and grasping the front leg of a 6-month-old white alpaca: It was 1994 and I was trimming toenails. An immediate feeling of panic leapt into my chest as I discovered a bloody puss between her toes: could this be foot and mouth disease, I naively wondered? I immediately called my vet, Dr Jerilynn Booher, and we pondered the problem. The female in question also had infected ears, hair loss, and small, puss-infused pimples on her nose. (It was not foot and mouth disease.)

Alpacas are susceptible to skin problems, and there are a wide-ranging number of possible causes. I made a trip to Peru shortly after my discovery of the puss-infected toes and as I was browsing through the used book section in a small bookstore off the main square in Arequipa, I found a slim, dog-eared volume on Andean livestock husbandry: *Instituto Veterinario de Investigaciones Tropicales Y De Altura (Ivita)*, edited by Dr. Manuel Moro S. and Dr. Saul Fernández Baca, and published in 1966. I opened the book to a page that contained the photograph seen below (Ex. A), which pictured a more advanced condition of what I had discovered on my female.



Ex. A

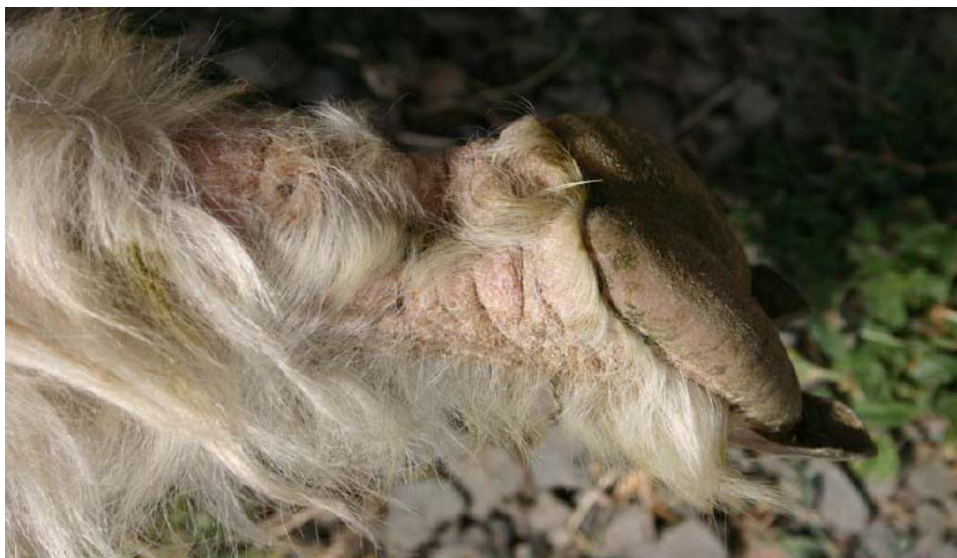After I returned to the U.S. and had the text describing the symptoms translated from Spanish to English, I realized the condition was the result of skin mites. I had stumbled onto the catalyst for a comprehensive Camelid skin cure that I call “witches brew”.



Ex. B Hair loss on face

The Symptoms

The skin condition in question is familiar to most alpaca owners – loss of hair on the nose and face, loss of hair at the ankles (Ex. C), or scabby skin in the hairless areas on the belly. This is accompanied by varying degrees of red thickened skin and puss-filled pimples in the hair loss areas and crusty ears with gobs of black, waxy material in the ear canal. (Not all symptoms appear at the beginning, in advanced cases this ear condition can turn into a foul-smelling, puss-filled infection.)



Ex. C Hair loss on ankles

The Myth

I am constantly inspecting alpacas at shows and seminars around the country and the world. The most common problems that I observe are funky skin conditions with the symptoms that I described above. If the owners have noticed the problem or spoken with their veterinarians about it, they most often tell me that it has been diagnosed as “zinc deficiency”. Some say they believe it is due to sunburn. Few, if any, have found an effective cure for the conditions they describe.

There is some basis to believe that these problems are attributable to the lack of zinc in an animal’s diet. The camelid medical books are full of descriptions—thick skin, hair loss, and pussy pimples—which they attribute to zinc responsive dermatitis (*The Veterinary Clinics of North America Food Animal Practice*, “Update on Llama Dermatology” by Rod A. W. Rosychuk, July, 1994, pg. 232, 233; *Medicine and Surgery of South American Camelids*, Murray E. Fowler, 1989, pg. 26; *The Complete Alpaca Book*, 2003, pg. 194.) However, as Norm Evans says in *The Alpaca Field Manual*, 2003, pg. 45, “I question that every skin problem in alpacas is a zinc responsive dermatitis. How many severe skin problems respond to zinc? I suggest five to ten percent.” My veterinarian, Dr. Paul Jones, agrees, saying he believes that “less than 5% of alpaca skin problems are related to zinc deficiency.” In fact, Dr. Evans believes that straight zinc oxide in the diet can “actually aggravate skin problems.”

The myth that suggests these skin problems are a result of sunburn is even harder to understand. It defies logic that animals that were domesticated under cloudless skies, over a shadeless plain, under a sun that is 15,000 feet closer to their face than almost any other large mammal on earth, would not have acclimated to the sun. I found, after a fairly extensive review of the existing literature on the subject, only one reference to sunburn being the root cause of camelid skin problems. I must say, upon reading the following quote, I had to smile. “Therapy for actinic dermatitis usually is not necessary, unless the condition is severe. Consideration should be given to sun restriction (especially between the hours of 10:00 am to 4:00 pm), topical sunscreens, and, possibly, glucocorticoid administration” (*The Veterinary Clinics of North America: Update on Llama Medicine*, July 1994, pg. 229.)

(Upon reading the above quote, I did not know whether to call PETA—People for the Ethical Treatment of Animals—and report the llama owners who neglected to slather their animals with suntan lotion or to contact the Quechua herders in the mountains of Peru to alert them to the wonders of New World medicine.)

But enough of the myths. There are accurate diagnoses of these skin maladies: mites and munge.

The Mites

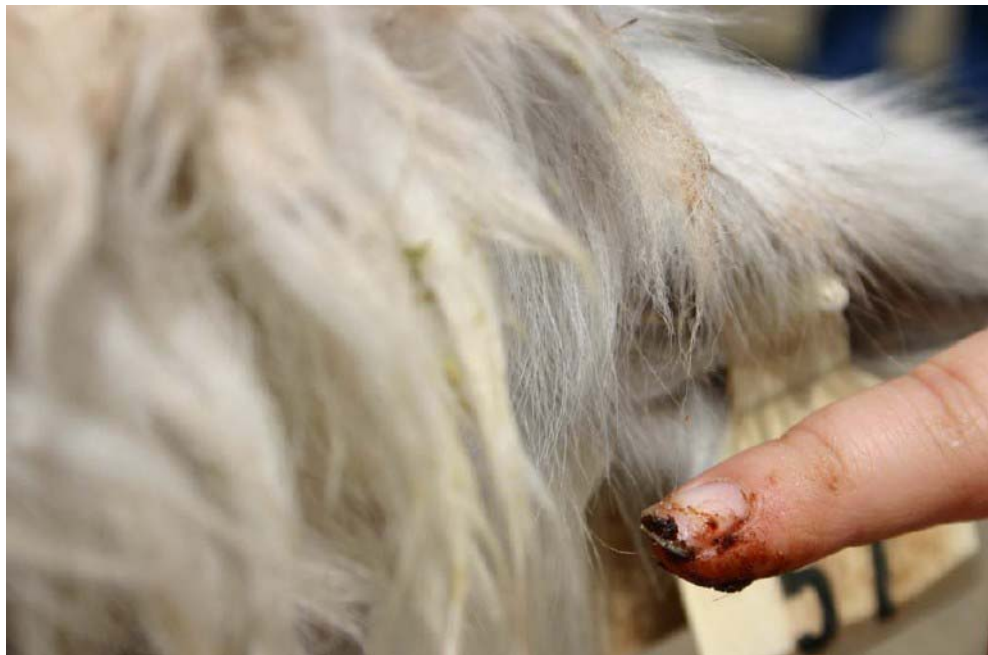The primary culprits in most problem skin cases are mites. There are three kinds of these critters that cause the majority of symptoms: *Sarcoptes scabii* (scabies), chorioptic, and psoroptes. (See *Medicine and Surgery of South American Camelids* by Murray E. Fowler, 1989, pg. 205-210.) Before I move on, here is a brief description of these little buggers:

Sarcoptes are round, fat mites with short legs who copulate on the surface of the skin, after which, the female burrows under the skin and lays her eggs in the tunnel she creates. These mites are often found on the alpacas lower legs, belly and tail but they can range over the entire animal.

Chorioptic mites are more elongated than the sarcoptes and they chew on the skin rather than burrowing. These mites are less common and do not cause as severe of a reaction as the sarcoptes. The chorioptic mites live entirely on the surface of the skin and are often found between the toes, in the ears, on the face and over the body. In Oregon the most common mite is the chorioptic.

Psoroptic mites: These oval shaped bloodsuckers live on the surface of the skin. There is some confusion as to whether these mites even occur on alpacas in the United States. *The Veterinary Clinics of North America, Food Animal Practice*, March 1989, pg. 223, reports that psoroptic mites have not been positively identified in llamas and alpacas in the United States, although they are a reportable disease. However, Murray Fowler, in *Camelid and Surgery of South American Camelids*, pg. 209 says he has diagnosed this mite in one American llama.

All of the above mites bite and suck, leaving behind a trail of red, itching, thickened skin that often creates puss pockets similar to a mild case of teenage acne. Many alpacas will have mites in their ears, which they will drop to the side of their head and scratch with their hind foot. Always check the inside of the ear to see if a black waxy substance is present (this condition can also be the result of ear ticks). This material is mite or tick feces and indicates a need for treatment. As bad as this condition looks, it can be cured in a fairly straight-forward fashion. But first we need to march on to the munge.



Ex. D Mites in the ear

The Munge

Ideopathic Nasal/Perioral Hyperkeratotic Dermatitis, or Munge, might also be the culprit of the above symptoms. Although alpacas at any age are susceptible to the munge, it is most common in animals four months to two years of age. The cause is unknown. It resembles a viral disease in sheep and goats commonly called “sore mouth” or “scabby mouth”. However, no particular virus has been identified as the

cause. The condition may be the result of immunodeficiency, bacterial infection, fungal infection or constant contact with an irritant like wet grass.

Munge lesions may resemble mite lesions but most commonly affect the lips and nose. The lesions include thickening and cracking of the skin at the corners of the mouth which leads to crusty scales of the lips and nose.

The Diagnosis

The diagnosis for the presence of mites and the identity of which species is present, can be made by your veterinarian from a skin scraping.

The Cure

Whatever the cause, I have been successfully treating all of the above symptoms for years with a concoction I call "witches brew". This solution was conjured up by Dr. Jerilynn Booher shortly after I returned from Peru with the book I found in Arequipa. The recipe follows:

Witches Brew Recipe

Ingredients:

2/3 pint mineral oil

1/5 pint DMSO

8 ml Ivermectin

5 cc Gentamycin (50 mg per ml)

Directions:

The "brew" needs to be applied to the affected area every three days for at least 15 days, maybe more. Make sure that you use rubber gloves when you are applying the mixture. At the beginning of the course of treatment, Dr. Jones recommends an injection of Ivermectin followed by another 15 days later. In addition, I have had a lot of success in curing ear mites by infusing each ear with ½ cc of Ivermectin at the beginning of treatment.

Dr. Norm Evans recommended a similar solution in his 2003 book, *The Alpaca Field Manual*, which he calls "Camelid Skin Mix". My vet, Dr. Paul Jones, decided that my name for the stuff, "Witches Brew", was not particularly professional, and he prescribes the same ingredients using the name, "Camelid Skin Solution".

This is how the ingredients interact to affect a cure: The DMSO delivers the Ivermectin through the crusty skin; the mineral oil holds the solution in place; and the Gentamycin acts as an antibiotic and clears up the infections that follow the mites. Please note that I am not, nor do I intend to be giving veterinarian advice here. You will need your veterinarian to make the diagnosis, prescribe the treatment and mix the solution.

I have, on occasion, suggested that an alpaca breeder use this formula and their veterinarian has said, after scraping the skin, "There are no mites." Or, they have insisted that the problem is zinc deficiency. One breeder reported to me that his veterinarian refused to make the solution available because the ingredients would "not mix properly" and they separated. When I shared this concern with Dr. Jones, he agreed, but said that if you simply shook the solution before applying, the problem would resolve itself. Ah, some things are just too simple.

If the sore mouth symptoms are really a virus or bacteria, a solution of Nolvasan Scrub (applied to the infected area) might help clear up the condition, but I would follow it with an application of "witches brew" to be safe. In fact, it does not hurt to scrub any affected skin area with Nolvasan before applying the witches brew. You may also want to move your alpacas to a clean pasture after treatment. The mites, or their eggs could collect in the soil and then be picked up by unaffected animals. In any case, I have found that the condition is not widely communicable among herd mates.

I have had many, many breeders thank me for recommending this solution over the years. For whatever reason, this solution works on munge and mites of every kind. In fact, in my experience, it even cures zinc deficiency and sunburn! (Just kidding, of course.)